

The Effect of Anterior Suspension Stitch at W''-Shaped İleal Neobladder on Continence

Sacit Nuri Gorgel*, Osman Kose, Ozan Horsanalı, Alper Cihat Erdal, Ugur Balci and Kutun Ozer

Department of Urology, Ataturk Training and Research Hospital, Izmir Katip Celebi University, Izmir, Turkey

***Corresponding Author:** Sacit Nuri Gorgel, Department of Urology, Ataturk Training and Research Hospital, Izmir Katip Celebi University, Izmir, Turkey, Tel: +90 532 6882910; Fax: +90 232 2431530; E-mail: sngorgel@hotmail.com

Citation: Sacit Nuri Gorgel, Osman Kose, Ozan Horsanalı, Alper Cihat Erdal, Ugur Balci and Kutun Ozer (2016) The Effect of Anterior Suspension Stitch at W''-Shaped İleal Neobladder on Continence. *Kidney Urol Res* 1: 001.

Copyright: © 2016 Sacit Nuri Gorgel et al. This is an open-access article distributed under the terms of the Creative Commons Attribution License, which permits unrestricted Access, usage, distribution, and reproduction in any medium, provided the original author and source are credited.

Abstract

Objective: To evaluate the effect of anterior suspension stitch during radical cystectomy and ileal neobladder urinary diversion on continence.

Methods: 176 male patients who underwent radical cystectomy and neobladder urinary diversion because of bladder cancer in our clinic. We analyzed 75 patients retrospectively, 36 with the placement of anterior suspension stitch Group 1 and 39 without anterior suspension stitch Group 2. Both groups were compared in terms of age, maximum urinary flow rate, post voiding residual urine volume, total, nighttime and daytime continence status. Incontinence status was evaluated by International Consultation on Incontinence Questionnaire-Short Form (ICIQ-SF)

Results: The two groups had no significant differences in their age, post voiding residual urine volume and maximum urinary flow rate. Total, nighttime and daytime continence rates were better in group 1. The mean International Consultation on Incontinence Questionnaire-Short Form score was significantly lower in group 1 ($p < 0.05$).

Conclusions: We found that the continence rates were significantly higher in patients with the anterior suspension stitch. This technique improves the quality of life of patients in the way of incontinence. The anterior suspension stitch during radical cystectomy and neobladder urinary diversion is a reliable and applicable procedure.

Keywords: Anterior Suspension; Stitch Bladder Cancer; Continence; Neobladder

Introduction

Bladder cancer is the ninth most commonly diagnosed cancer worldwide, with more than 380,000 new cases each year and more than 150,000 deaths per year, and an estimated male-female ratio of 3.8:1.0 [1]. At any one time, 2.7 million people have a history of urinary bladder cancer[2]. According to a critical systematic review, bladder cancer is the most expensive malignancy to treat on a per-patient basis due to the requirement for lifelong routine monitoring and treatment from diagnosis to mortality [3,4].

Over the past 10 years, great progress has been made in our understanding of bladder cancer [5,6]and radical cystectomy with orthotopic ileal neobladder is frequently performed for muscle-invasive bladder cancer and high-risk superficial tumors that are unresponsive to intravesical therapy [7,8]. A normal lower urinary tract should be able to achieve efficient and low-pressure bladder filling, low-pressure urine storage with perfect continence and periodic complete voluntary urine expulsion, again at low pressure [9]. The physiological function of the orthotopic bladder is also extremely close to the original bladder compared with other traditional urinary diversion surgeries [10].

Functional results are so important after surgery in point of quality of life as well as oncologic results. Many suture techniques have been developed to improve continence especially after radical prostatectomy. In this

study, we aimed to evaluate the effect of anterior suspension stitch on continence in patients who underwent radical cystectomy and ileal neobladder urinary diversion

Material and Methods

Between 1990 and 2014, 550 patients who underwent radical cystectomy operation were performed because of bladder cancer. We performed orthotopic ileal W shaped neobladder with serous-lined extramural tunnel (Figure 1) [11] in 176 male patients following radical cystectomy as urinary diversion. Of these patients, 84 had a follow-up of more than 1 year and enrolled the study.

We analyzed 75 patients, 36 with the placement of anterior suspension stitch Group 1 and 39 without anterior suspension stitch Group 2 retrospectively. Both groups were compared in terms of age, maximum urinary flow rate, post voiding residual urine volume, total, nighttime and daytime continence status. Incontinence status was evaluated by International Consultation on Incontinence Questionnaire-Short Form (ICIQ-SF) [12].

Full continence is defined as daytime and nighttime dryness without need of a pad. Five patients with urethropouch anastomosis stricture and four patients with clean intermittent catheterisation were excluded. Numeric and non-numeric data were analyzed with non-paired student t test and chi-square test respectively. P value of <0.05 was considered significant

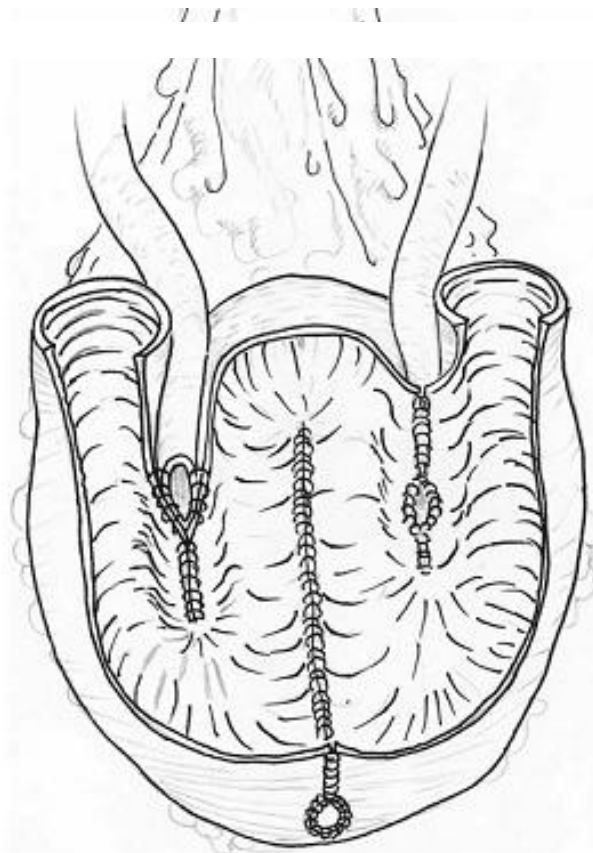


Figure 1. Orthotopic "W" ileal neobladder

Surgical Techniques

After ligation of the dorsal venous complex using an absorbable polyglactin suture anterior suspension stitch was

carried out prior to ileal neobladder-urethral anastomosis. An anterior suspension stitch is passed between the sutured dorsal vein complex and periosteum on the pubic bone figure 2.

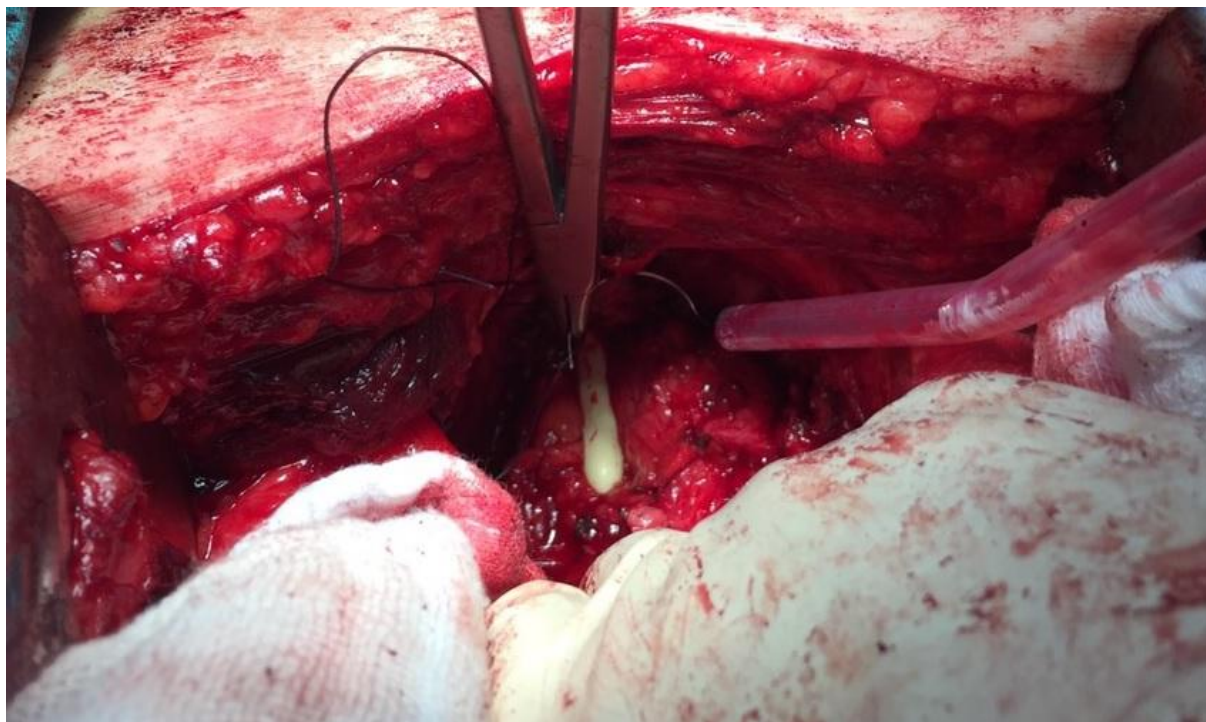


Figure 2. Anterior suspension stitch is passed between the sutured dorsal vein complex and periosteum

Results

All patients were men. The mean age of patients was 65.9 ± 8.9 (42–79) years. The two groups had no significant differences in their age, post voiding residual urine volume and maximum urinary flow rate. Total, nighttime and daytime continence rates were better in group 1. The mean International Consultation on Incontinence Questionnaire-Short Form (ICIQ-SF) score was significantly lower in group 1 (Table1) ($p < 0.05$).

Maximum urinary flow rate was evaluated by uroflowmetry. In patients with anterior suspension stitch; the mean maximum urinary flow rate was 17.3 ± 9.4 (11–26) and 16.8 ± 7.6 (12–25) in other group ($p = 0.166$). Post voiding residual urine volume was assessed by ultrasound and two groups were similar (0.09).

Daytime continence (86%), nighttime continence (55%) and total continence (69%) rates were significantly higher in group 1 ($p = 0.04$, 0.02 and 0.01 respectively). The mean ICIQ-SF score was 7.1 ± 3.1 statistically lower in patients with anterior suspension stitch ($p = 0.01$).

Discussion

Although urinary diversion following radical cystectomy can be carried out in several ways, orthotopic

neobladder has been recognized as a relatively effective surgery [13]. Considering the functional association between the bladder and bowel, the potent clinical application values of orthotopic ileal neobladder following radical cystectomy have been widely assessed [14-15]. In our clinic, the number of ileal neobladder urinary diversion has increased over the last ten years. Before ten years, we performed especially bricker and ureterocutaneostomy after radical cystectomy as urinary diversion.

Neobladders are a form of continent urinary diversion but are not free of continence issues. Continence rates vary with surgical technique, length of time after the operation and time of day. Total continence rates with neobladders range from 22.3% to 63.2% at 12 months postoperatively [16,17] and 17.7–74.5% beyond 40 months postoperatively [18,19]. Daytime continence rates vary from 21.4% to 99.0% at 3–48 months postoperatively [17-22]. The Abol-Enein and Ghoneim modification of the W pouch, a commonly used technique, recorded a daytime continence rate of 93.3% [23]. Interestingly, Sevin et al. demonstrated a gradually increasing daytime continence rate with time; at 6, 12, 24, 36 and ≥ 48 months postoperatively, daytime continence rates were 63%, 70%, 76%, 88% and 92%, respectively [24].

Table 1. Uroflowmetry and continence parameters in both groups

	Group 1	Group 2	p
Number of patients	36	39	
Age	63.7±7.2 (56–79)	64.8±9.1 (42–73)	0.352 ^a
Post voiding residual urine volume	98.4 ± 104	101.3 ± 98	0.09 ^a
Maximum urinary flow rate (ml/s)	17.3 ± 9.4 (11–26)	16.8 ± 7.6 (12–25)	0.166 ^a
Daytime continence	31 (86%)	31 (79%)	0.04 ^b
Nighttime continence	20 (55%)	15 (38%)	0.02 ^b
Total continence	25 (69%)	17 (43%)	0.01 ^b
ICIQ-SF	7.1 ± 3.1	9.4 ± 5.1	0.01 ^a
^a non paired student t test, ^b chi square test			

Furthermore, there were no significant difference in daytime incontinence rates between patients with a modified S-pouch neobladder and a healthy control population without urinary diversion (10% vs. 9.3%) [25]. Patients with a neobladder are generally less continent at night than in the daytime. In the nighttime, 18.9–79%, 74%, 23%, 77.6% and 44% of patients were continent at 12, 38 (mean), 44 (median), 48 and 54 (mean) months postoperatively, respectively [17-19, 21, 22, 24, 26]. In our study, daytime continence rate was 91%, nighttime continence rate was (55%) total continence rate was (69%) in patients with anterior suspension stitch. In addition, daytime and nighttime continence are also key factors effecting patients' health-related quality of life [27, 28]. According to this results, this technique can be useful to increase quality of life.

Continence is very important after surgery in point of quality of life. Many suture techniques have been developed to improve continence especially after radical prostatectomy; on the other hand, there is no clear knowledge in the literature about radical cystectomy and neobladder urinary diversion.

The anterior suspension technique was first described in radical prostatectomy, which can help control venous bleeding and provide recapitulation of the puboprostic ligaments, supporting the striated sphincter. The theorized mechanism on continence of this technique is

that it provides anatomic support for the urethra, improvement of the urethral length, and stabilize the urethra and the striated sphincter in an anatomic position [29-31].

We thought that the same mechanisms could be useful in neobladder urinary diversion. We have applied this technique in 36 patients. We found that the daytime, nighttime and total continence rates was significantly higher in patients with the anterior suspension stitch, furthermore, the mean International Consultation on Incontinence Questionnaire-Short Form score was significantly lower in these patients.

There were three limitations in our study. First, we enrolled the study only male patients, this technique should be performed in female patients. Second, the study was designed retrospectively. Third, the *sample size* may have been to *small*, and further larger *studies* are required to confirm these results

Conclusions

We found that the continence rates was significantly higher in patients with the anterior suspension stitch. This technique improves the quality of life of patients in the way of incontinence. The anterior suspension stitch during radical cystectomy and neobladder urinary diversion is a reliable and applicable procedure.

References

1. Siegel R, Naishadham D, Jemal A (2013) Cancer statistics, 2013. *CA Cancer J Clin* 63:11-30.
2. Ploeg M, Aben KK, Kiemeny LA (2009) The present and future burden of urinary bladder cancer in the world. *World J Urol* 27:289-293.
3. Botteman MF, Pashos CL, Redaelli A, Laskin B, Hauser R (2003) The health economics of bladder cancer: a comprehensive review of the published literature. *Pharmacoeconomics* 21: 1315–1330.
4. Christoforidou EP, Riza E, Kales SN, Hadjistavrou K, Stoltidi M, et al. (2013) Bladder cancer and arsenic through drinking water: a systematic review of epidemiologic evidence. *J Environ Sci Health A Tox Hazard Subst Environ Eng* 48:1764–1775.
5. Rodriguez Faba O, Gaya JM, López JM, Capell M, De Gracia-Nieto AE, et al. (2013) Current management of non-muscle-invasive bladder cancer. *Minerva Med* 104: 273–286.
6. Cheung G, Sahai A, Billia M, Dasgupta P, Khan MS (2013) Recent advances in the diagnosis and treatment of bladder cancer. *BMC Med* 11:13.
7. Clifton MM, Tollefson MK (2013) Anatomic basis of radical cystectomy and orthotopic urinary diversion in female patients. *Clin Anat* 26:105–109.
8. Kübler H, Gschwend JE (2011) Ileal neobladder in women with bladder cancer: cancer control and functional aspects. *Curr Opin Urol* 21:478–482.
9. Chapple C (2011) Overview on the lower urinary tract. *Handb Exp Pharmacol* 202:1–14.
10. Herdiman O, Ong K, Johnson L, Lawrentschuk N (2013) Orthotopic bladder substitution (Neobladder): part II: postoperative complications, management, and long-term follow-up. *J Wound Ostomy Continence Nurs* 40:171–180.
11. Marim G, Bal K, Balci U, Girgin C, Dincel C (2008) Long-term urodynamic and functional analysis of orthotopic "W" ileal neobladder following radical cystectomy. *Int Urol Nephrol* 40:629-636.
12. Uebersax JS, Wyman JF, Shumaker SA, McClish DK, Fantl JA (1995) Short forms to assess life quality and symptom distress for urinary incontinence in women: the Incontinence Impact Questionnaire and the Urogenital Distress Inventory. *Continence Program for Women Research Group Neurourology and Urodynamics* 14: 131-139.
13. Roghmann F, Becker A, Trinh QD, Djahagirian, O, Tian Z, et al. (2013) Updated assessment of neobladder utilization and morbidity according to urinary diversion after radical cystectomy: A contemporary US-population-based cohort. *Can Urol Assoc J* 7:E552–E560.
14. Hart S, Skinner EC, Meyerowitz BE, Boyd S, Lieskovsky G, et al. (1999) Quality of life after radical cystectomy for bladder cancer in patients with an ileal conduit, cutaneous or urethral kock pouch. *J Urol* 162:77–81.
15. Guan Z, Li J, Yang R (2013) Impacts of different grafts for bladder reconstruction on postoperative recovery of the patients. *Nan Fang Yi Ke Da Xue Xue Bao* 33:1250–1252.
16. Aleksic P, Bancevic V, Milovic N, Kosevic B, Stamenkovic DM, et al. (2010) Short ileal segment for orthotopic neobladder: A feasibility study. *Int J Urol* 17:768–773.
17. Ahmadi H, Skinner EC, Simma-Chiang V, Miranda G, Cai J, et al. (2013) Urinary functional outcome following radical cystoprostatectomy and ileal neobladder reconstruction in male patients. *J Urol* 189:1782–1788.
18. Meyer JP, Drake B, Boorer J, Gillatt D, Persad R, et al. (2004) A three-centre experience of orthotopic neobladder reconstruction after radical cystectomy: Initial results. *BJU Int* 94:1317–1321.
19. Novara G, Ficarra V, Minja A, De Marco V, Artibani W (2010) Functional results following vesica ileale Padovana (VIP) neobladder: Midterm follow-up analysis with validated questionnaires. *Eur Urol* 57:1045–1051.
20. Girgin C, Sezer A, Ozer K, Tarhan H, Bolukbasi A, et al. (2004) Comparison of three types of continent urinary diversions in a single center. *Scientific World Journal* 4(Suppl 1):135–141.
21. Studer UE, Burkhard FC, Schumacher M, Kessler TM, Thoeny H, et al. (2006) 20-years experience with an ileal orthotopic low pressure bladder substitute – Lessons to be learned. *J Urol* 176:161–166.
22. Deliveliotis C, Alargoff E, Skolarikos A, Varkarakis I, Argyropoulos V, et al. (2001) Modified ileal neobladder for continent urinary diversion: Experience and results. *Urology* 58:712–716.
23. Abol-Enein H, Ghoneim MA (2001) Functional results of orthotopic ileal neobladder with serous-lined extramural ureteral reimplantation: Experience with 450 patients. *J Urol* 165:1427–1432.
24. Sevin G, Soyupek S, Armagan A, Hoscan MB, Oksay T (2004) Ileal orthotopic Neobladder (modified Hautmann) via a shorter detubularized ileal segment: experience and results. *BJU Int* 94:355–359.
25. Protogerou V, Moschou M, Antoniou N, Varkarakis J, Bamias A, et al. (2004) Modified S-pouch neobladder vs ileal conduit and a matched control population: A quality-of-life survey. *BJU Int* 94:350–354.
26. Thulin H, Kreicbergs U, Wijkström H, Steineck G, Henningsohn L (2010) Sleep disturbances decrease self-assessed QoL in individuals who have undergone cystectomy. *J Urol* 184:198–202.
27. Weijerman PC, Schurmans JR, Hop WC, Schroder FH, Bosc JL (1998) Morbidity and quality of life in patients with orthotopic and heterotopic continent urinary diversion. *Urology* 51:51–56.
28. Steers WD (2000) Voiding dysfunction in the orthotopic neobladder. *World J Urol* 18:330–337.

29. Hurtes X, Rouprêt M, Vaessen C, Pereira H, Faivre d'Arcier B, et al. (2012) Anterior suspension combined with posterior reconstruction during robot-assisted laparoscopic prostatectomy improves early return of urinary continence: a prospective randomized multicentre trial. *BJU Int* 110: 875-883.
30. Walsh PC (1998) Anatomic radical prostatectomy: evolution of the surgical technique. *J Urol* 160:2418-2424.
31. Eastham JA, Kattan MW, Rogers E, Goad JR, Ohori M, et al. (1996) Risk factors for urinary incontinence after radical prostatectomy. *JUrol* 156: 1707-1713.

Please Submit your Manuscript to Cresco Online Publishing
<http://crescopublications.org/submitmanuscript.php>