

## Perfusion Changes in Liver Metastases from Pancreatic Neuroendocrine Tumours during Everolimus Treatment

Mirko D'Onofrio<sup>1\*#</sup>, Sara Cingarlini<sup>2\*</sup>, Silvia Ortolani<sup>2</sup>, Stefano Crosara<sup>1</sup>, Riccardo De Robertis<sup>3</sup>, Paola Vallerio<sup>4</sup>, Elisabetta Grego<sup>2</sup>, Andrea Ruzzenente<sup>5</sup>, Luca Landoni<sup>6</sup>, Aldo Scarpa<sup>7</sup>, Roberto Pozzi Mucelli<sup>1\*</sup> and Giampaolo Tortora<sup>2\*</sup>

<sup>1</sup>Department of Radiology, Comprehensive Cancer Center, G.B. Rossi University Hospital of Verona, Piazzale LA, Scuro 10, 37134 Verona, Italy

<sup>2</sup>Oncology Department, Comprehensive Cancer Center, G.B. Rossi University Hospital of Verona, Piazzale LA, Scuro 10, 37134 Verona, Italy

<sup>3</sup>Department of Radiology, Casa di Cura Pederzoli, Via Monte Baldo 24, Peschiera del Garda (Verona), Italy

<sup>4</sup>Internal Medicine, Comprehensive Cancer Center, G.B. Rossi University Hospital of Verona, Piazzale LA, Scuro 10, 37134 Verona, Italy

<sup>5</sup>Hepato-biliary Surgery, Comprehensive Cancer Center, G.B. Rossi University Hospital of Verona, Piazzale LA, Scuro 10, 37134 Verona, Italy

<sup>6</sup>Pancreatic Surgery, Comprehensive Cancer Center, G.B. Rossi University Hospital of Verona, Piazzale LA, Scuro 10, 37134 Verona, Italy

<sup>7</sup>Pathology Department, Comprehensive Cancer Center, G.B. Rossi University Hospital of Verona, Piazzale LA, Scuro 10, 37134 Verona, Italy

\*Equally Contributors

#Corresponding Author

**#Corresponding Author:** Prof. Mirko D'Onofrio, Department of Radiology, Azienda Ospedaliera Universitaria Integrata, University of Verona, Piazzale L.A. Scuro 10, 37134 Verona, Italy; Tel: +39 0458124301, E-mail: [mirko.donofrio@univr.it](mailto:mirko.donofrio@univr.it)

**Citation:** Mirko D'Onofrio, Sara Cingarlini, Silvia Ortolani, Stefano Crosara, Riccardo De Robertis, Paola Vallerio, Elisabetta Grego, Andrea Ruzzenente, Luca Landoni, Aldo Scarpa, Roberto Pozzi Mucelli and Giampaolo Tortora (2016) Perfusion Changes in Liver Metastases from Pancreatic Neuroendocrine Tumours during Everolimus Treatment. *Cancer Res Oncol* 2: 009.

**Copyright:** © 2016 Mirko D'Onofrio, et al. This is an open-access article distributed under the terms of the Creative Commons Attribution License, which permits unrestricted Access, usage, distribution, and reproduction in any medium, provided the original author and source are credited.

## Abstract:

**Background:** Preliminary studies have suggested a role for perfusion CT (PCT) in predicting early response to anti-angiogenic therapies in pancreatic neuroendocrine tumors (PanNETs). Despite this, perfusional modifications induced by everolimus in PanNET liver metastases (LM) are not completely understood.

**Objective:** To evaluate modifications of perfusional parameters assessed by PCT in LM from PanNETs during everolimus treatment, aiming to identify responding patients at an early stage of treatment.

**Methods:** All patients with LM from G1-2 PanNETs undergoing everolimus treatment between January 2013 and January 2015 were prospectively evaluated with PCT at baseline (T0), after 2 (T1) and 4 (T2) months of therapy. Treatment response was evaluated on a per lesion base using RECIST 1.1 criteria. Size, perfusion (PF), blood volume (BV), peak enhancement intensity (PEI) and time to peak (TTP) of each lesion were calculated; morphological and perfusional modifications were compared between responder and non-responder lesions.

**Results:** Thirty-three LM from nine patients with G1-2 PanNETs were prospectively evaluated: 23/33 (69.7%) were responders, 10/33 (30.3%) non-responders. Among perfusional parameters, only PEI significantly differed between the two groups at baseline ( $p=0.043$ ). BV increase was the most significant perfusional modification to identify responding lesions, even at an early stage of treatment (T1), with high positive predictive value (89.47%). A trend towards PEI decrease in responding lesions was observed; combining PEI decrease with BV increase did not improve response prediction. PF and TTP modifications were not significantly different between responders and non-responders.

**Conclusions:** P-CT seems to be useful for response prediction to everolimus in LM from PanNETs. Baseline PEI values are significantly higher in responding compared to nonresponding lesions. Significant BV increase was found in responding lesions, with high predictive value for response even in an early phase.

**Keywords:** Perfusion CT; Perfusion; Pancreatic neuroendocrine tumor; Everolimus; Predictive biomarkers.

## Background

Pancreatic neuroendocrine neoplasms (PanNENs) represent about 1.3% of all solid tumors of the pancreas, with high prevalence and increasing incidence. Despite an indolent behaviour, PanNENs may have a malignant course [1, 2], with invasion of adjacent organs, regional or distant metastases. Basing on morphological features and proliferative activity, PanNENs are divided into well differentiated (PanNETs G1 and 2, with Ki67 index of <2% and 2-20%, respectively) and poorly differentiated forms (PanNECs, G3, with Ki67 index >20%) [3].

Well-differentiated PanNETs usually present high vascularization, with diffuse expression of pro-angiogenic molecules as the vascular endothelial growth factor (VEGF) [4]. This is the rationale for the use of agents that directly or indirectly inhibit angiogenesis: among them, sunitinib and everolimus significantly improved PFS in phase III RCTs in advanced, progressive PanNETs, and are currently approved by main regulatory agencies with such indication [5, 6].

A major limitation in the use of targeted agents relays in the difficult evaluation of tumour response. RECIST 1.1 are the only validated criteria [7] but, even if actually used in

clinical trials, their accuracy is largely debated when applied to drugs that induce tissue modifications rather than tumor shrinkage, and may underestimate clinical benefit [8].

Choi and mRECIST criteria include changes in tumor enhancement on CT and demonstrated better correlation with clinical outcome in HCC and GIST [9-13]. Nevertheless, their potential in predicting drug response in PanNETs is still under debate; for this reason, there is a compelling need of new parameters of response that should consider also perfusional and functional modifications.

Perfusion CT (P-CT) can assess the vascular supply of tumours through the analysis of temporal changes in the attenuation in blood vessels and tissues [14]. It allows highly reproducible measurements of tumour vascular physiology and construction of regional maps of tumour blood flow, blood volume, time to peak and peak enhancement intensity. In oncologic imaging, P-CT has been applied in both animal models and humans, demonstrating its potential in lesion characterization, tumour staging and possibly prognostication in different tumor types (brain, liver, rectum, lung, pancreas, head and neck) [15-23]; its role in predicting and/or evaluating response to treatment is intriguing.

Preliminary studies in neuroendocrine tumors suggest a significant correlation between P-CT parameters and intratumoral microvascular density (MVD), tumor grade, microscopic vascular involvement and both lymphnode and liver metastases [24]. As a functional biomarker, P-CT has been tested in the evaluation of metastatic neuroendocrine tumors treated with interferon, bevacizumab, and everolimus (alone and in association), demonstrating its capability in detecting early modifications in perfusion parameters [25-27].

The correlation between such modifications and treatment response or clinical outcome is under investigation.

## Purpose

The aims of this study were to describe the modifications detected by P-CT in liver metastases from PanNETs during everolimus treatment and to evaluate possible correlations between tumor perfusion changes and clinical outcome in terms of progression free survival.

## Methods

Ethical board approval was waived. All patients who underwent treatment with everolimus for well-differentiated (G1-2) pancreatic neuroendocrine tumour metastatic to the liver between January 2013 and December 2014 were prospectively evaluated with PCT. Demographics, radiological features and treatment outcomes were collected and analysed.

## Patients

Inclusion criteria included age > 18 years; histological diagnosis of well-differentiated (G1-2) PanNET (percutaneous or endoscopic US-guided biopsy); advanced progressive disease in the 6 months preceding the enrolment; presence of measurable liver metastases that could be evaluated as target lesions at baseline and during therapy.

Exclusion criteria included: previous treatment with trans arterial (chemo) embolization (TAE/TACE), local ablative techniques, PRRT; contraindications to CT (e.g.: kidney failure, previous anaphylaxis or other adverse reactions to iodinated contrast); contraindications for the use of Everolimus.

## Treatment

Patients were treated with continuous oral Everolimus (Afinitor, Novartis) therapy at the daily dose of 10 mg in association with best supportive care; a treatment cycle was

considered of 28 days. Safety and tolerability of the drug were assessed at the beginning of each cycle from initiation of study treatment until at least 28 days after the last dose of study drug by standard monitoring methods (CTCAE criteria v4.0). For patients who reported any relevant toxicity (G3-4 according to CTCAE), dose adjustments (e.g. dose reductions until 5 mg daily or 5 mg every other day) or dose interruptions were allowed. Best supportive care could include the use of somatostatin analogues (SSA) when clinically indicated.

## Perfusion CT Technique

Perfusion CT studies were performed at baseline (T0) and after 2 (T1) and 4 (T2) months of everolimus treatment.

All perfusion CT examinations were performed with a 64-row multidetector CT scanner (Brilliance 64; Philips, Eindhoven, The Netherlands). Each examination was performed after a minimum fast of 6 h, with patients in supine position with their arms behind their head, during superficial and regular free-breath. An unenhanced scan was acquired before PCT to select the target volume. Repeated sequential scans were performed during the administration of 60 ml of iodine contrast agent (iopromide, Ultravist 370, Bayer Schering Pharma AG, Berlin, Germany) administered with a double-syringe injector (Stellant, MadRad, Indianola, PA, USA) at an injection rate of 5 ml/s followed by 40 ml of saline solution at the same flow rate.

CT scanning parameters included 120 kVp (for a slope method based scanning protocol, which is very sensitive to the image noise, a higher voltage has to be used than for a deconvolution method), tube current of 100 mAs/slice, gantry rotation time of 0.4 sec, increment 5 mm, 5-mm slice thickness and 100 mm in length. 64 slice CT scanners allow an axial coverage of about 40 mm, Using toggling table technique during dynamic images acquisition, axial coverage could be extended to 100 mm, Scanning started 7 sec after starting contrast material injection and images was acquired at every 10 seconds for 60 seconds, and later at 82, 97, 117 seconds, for a total of 200 images.

## Image Data Analysis

Image data were processed on a workstation (Extended Brilliance Workspace V4.5.2.40007, Philips, Eindhoven, and The Netherlands) loaded with commercial perfusion CT software (CT Perfusion Software, Philips, Eindhoven, The Netherlands) based on slope method of analysis. An abdominal radiologist with 10 years of experience in pancreatic imaging (M.D) reviewed all images. For each patient, 1 to 7 hepatic target lesions were selected.

The arterial input needed for perfusion analysis was obtained by manually drawing a circular region of interest (ROI) within the abdominal aorta at the level of the celiac trunk, being careful to avoid any parietal calcification. A single ROI was manually drawn within each target lesion; the axial slice in which the lesion had the maximum diameter was chosen for the placement of the ROI.

### Definition of Response

Treatment response was evaluated by means of RECIST1.1 criteria as reference standard.

For the purpose of our study, we considered as “responder” patients those with disease control during everolimus treatment lasting at least 11 months; this boundary was chosen based on the observed mPFS in the phase III trial of everolimus in advanced, well-differentiated, progressive PanNETs [6].

For the separate evaluation of each lesion we used a dimensional criteria adapted from the RECIST criteria in order to define a lesion as stable (< 30% decrease or < 20% increase in the maximum diameter) or progressive (> 20% increase in the maximum diameter); to avoid possible transient modifications, the progressive trend had to be confirmed in two subsequent imaging studies. Accordingly, we defined a “responder lesions” those who did not show progression before 11 months, while lesions progressing before 11 months were considered “non-responders”.

### Statistical Analysis

Morphological and perfusion features at baseline and during everolimus treatment of each target lesion were recorded. A comparison between responder- and non-responder lesions was made for morphological and perfusional variables at T0, T1 and T2. After assessing absolute modifications in each parameter separately for responding and non-responding lesions with repeated Anova tests, we compared the mean values of responding and non-responding lesions using one-way Anova test. Chi Square test was used to compare different trends between groups for categorical variables. A p value < 0.05 was considered statistically significant. Sensitivity, specificity, positive and negative predictive values of relevant modifications was calculated.

### Results

#### Study Population

Twelve consecutive patients with G1-2 PanNETs suitable for everolimus treatment were prospectively enrolled. Two patients were excluded because their liver lesions were deemed too small to be analysed with perfusion CT; one patient was excluded because of worsening chronic renal failure after the second perfusion CT examination.

Our final study population included 9 patients; demographics and clinical characteristics are summarized in Table 1.

At baseline, a total of 33 liver target lesions were selected; every target lesion was evaluated during everolimus treatment.

Table 1 : Clinical features of the 9 patients that underwent perfusion CT study.	
<b>Gender</b>	
Male	4 (44%)
Female	5 (56%)
<b>Age, y</b>	62.44 (47-74)
<b>Functioning</b>	
yes	0 (0%)
no	9 (100%)
<b>Grade</b>	
G1	1 (11%)
G2	8 (89%)
<b>Previous treatment*</b>	
yes	4 (44%)

	no	5 (56%)
<b>Concomitant SSA</b>	yes	9 (100%)
	no	0 (0%)
Categorical variables are expressed as number (%). Continuous variables are reported as mean values (range). * SSA monotherapy as antiproliferative treatment excluded.		

## Per-patient Analysis

Overall, in this patient cohort, everolimus led to a disease control rate during the treatment period of 77.8%, with stable disease as best objective response in all cases, (no partial responses were observed); the remaining 2 patients (22.2%) had disease progression during the study.

Globally, 6/9 patients had prolonged benefit from everolimus treatment (> 11 months) and were therefore considered “responders”; 3 patients obtained minimal (disease control for less than 11 months, 1 patient) or no benefit (2 patients) from everolimus and were considered “non-responders”.

Considering the per-Patient evaluation, Patient no 1 (**P1**) had 3 hyper vascular lesions at T0, 3 hyper vascular lesions at T1; 2 hyper vascular and 1 isovascular lesions were found at T2. The single lesion of **P2** was hyper vascular at T0, at T1 and at T2. **P3** had 7 hyper vascular lesions at T0, 7 hyper vascular lesions at T1; lesions became heterogeneous at T2 (3 hyper vascular and 4 isovascular lesions). The single lesion of **P4** was hyper vascular at T0, at T1 and T2. **P5** had 3 ipovascular and 1 isovascular lesions at T0 and 4 hypo vascular lesions both at T1 and T2. **P6** had 6 hyper vascular at T0, T1 and T2. **P7** had 6 isovascular lesions at T0 and at T1 and 6 hypo vascular lesions at T2. The single lesion of **P8** was hypo vascular at T0, at T1 and T2. **P9** had 3 hyper vascular at T0, at T1 and T2.

The intra-Patient lesions heterogeneity was therefore low at baseline and subsequently increased.

## Per-lesion Analysis

### Morphology and Vascularization

At baseline, the mean maximum diameter of target lesions was 17.8±7.4 mm (range, 9-31.5 mm).

After two months of everolimus treatment (T1), 5/33 target lesions had an increase greater than 20% of their maximum diameter; four of them demonstrated an additional increase at T2, thus configuring a “per-lesion”-progressive status.

At T2, 6/33 lesions had a >20% size increase; one lesion that increased at T1 showed a diameter reduction at T2, and was therefore classified as stable; the remaining 26 target lesions were substantially stable (no > 20% increase nor >30% decrease) during the study period.

Imaging studies conducted beyond the end of the perfusion-CT study period confirmed a dimensional stability for at least 11 months in 23/33 target lesions, which were therefore considered “responder-lesions”.

Ten lesions had a >20% size increase within 11 months since the beginning of everolimus treatment, and were therefore considered as “non-responder-lesions”.

Responder lesions were significantly larger than non-responder lesions at baseline (mean diameter: 20.7 +/- 6.4 versus 11.2 +/- 4.8 mm, p < 0.001).

The qualitative analysis of such lesions conducted at baseline classified 21/33 lesions (63.7%) as hyper vascular, 8/33 (24.2%) as isovascular and 4/33 (12.1%) hypo vascular. After 2 months of therapy (T1), 22 (66.7%) were hyper vascular, 6 (18.2%) isovascular and 5 (15.1%) hypo vascular; after 4 months (T2), 17 (51.5%) resulted hyper vascular, 5 (15.1%) isovascular and 11 (33.4%) hypo vascular.

Hyper vascular lesions more frequently responded to treatment compared with iso/hypo vascular lesions (76.2% vs 58.3%), though this difference was not statistically significant (p 0.43). When considering only hyper vascular lesions, baseline maximum diameter remained significantly associated with response, with responder lesions being larger than non-responder lesions (20.6 +/- 5.8 mm versus 10.9 +/-5.7 mm, p 0.004).

## Perfusion

Baseline and post-treatment values of perfusion parameters for each target lesion were recorded and analyzed.

At baseline, responder lesions showed higher PF values compared to non-responder lesions (mean 148.1 +/- 111.8 vs 82.8 +/- 68.2 ml/100 g of tissue/min, respectively; p 0.098). Over time, PF slightly increased in both responder and non-responder lesions, though without statistical significance (p 0.731 and 0.607, respectively). When considering PF modifications as a categorical variable (PF decrease vs PF stability/increase), no differences were found at T1 (p 0.678), T2 (p 0.341), or at 'any' point during the study treatment (p 0.283) between responder and non-responder lesions.

In terms of TTP, responder and non-responder lesions showed no differences at baseline (mean 19.6 +/- 14 vs 25.8 +/- 18 s, respectively; p 0.289). Over time, mean TTP values showed a trend towards initial decrease and subsequent increase in responder lesions (p.0648), while to early increase (T1) with subsequent stabilization in non-responder lesions (p 0.444). This led to an observed significant difference in mean TTP values at T1 between responder and non-responder lesions (p 0.002), which was lost at T2 (p 0.078). Increase in TTP, intended as a categorical variable, from baseline to T1 was significantly more frequent in nonresponder than in responder lesions (p 0.032), while from T0 to T2 no difference was found (p 0.592). An increase in TTP at any time during the study period was noticed more frequently in non-responder lesions (80%) than in responder lesions (43.5%), with borderline statistical significance (p 0.053).

Considering PEI, at baseline, significantly higher values were seen in responder compared to non-responder lesions (mean 72.8 +/- 49.2 versus 39.4 +/- 10.1; p 0.043). Mean

PEI values showed a borderline significant, progressive decrease in responder lesions (p 0.06), while a constant increase in non-responder lesions (p 0.523). A PEI decrease from baseline to T1 was more frequent in responder lesions (69.6%) compared to nonresponder lesions (40%), although in a non-significant way (p 0.110); similarly, from baseline to T2 (65.2% and 40%, respectively; p 0.178). In general, a PEI decrease at any time of the study period resulted significantly more frequent in responder compared to non-responder lesions (82.6% and 40%, respectively; p 0.014).

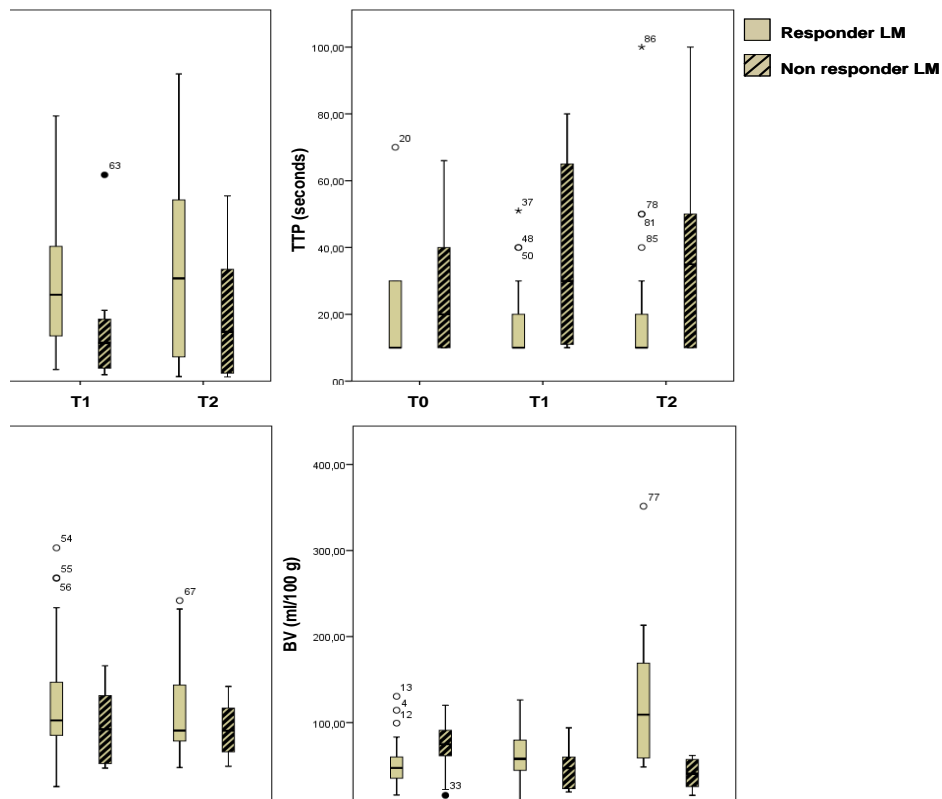
Although no differences were found in mean BV values between responder- and non-responder lesions at baseline (mean: 51.7 +/- 30.8 and 70.6 +/- 32.3 ml/100 g of tissue, respectively; p 0.121) nor at T1 (61.9 +/- 28 versus 46.8 +/- 24.4; p 0.150), at T2 responder-lesions showed significantly higher mean BV value compared to non-responder lesions (124.11 +/- 73.75 and 39.9 +/- 17.52 ml/100 g of tissue, respectively; p 0.001). Over time, indeed, mean BV values progressively, significantly increased in responder lesions (p 0.001) and decreased in non-responder lesions (p 0.111). When considering BV modifications as a categorical variable (BV increase vs BV stability/decrease), we found a significant difference between the two groups even at T1 (p 0.004), subsequently confirmed at T2 (p < 0.001); in general, a BV increase at any point of the study treatment was more frequent in responder than in non-responder lesions (p 0.001).

A synthesis of the significant differences found in each perfusional parameter over the study treatment period is reported in Table 2; a boxplot illustrating such differences (Figure 1), and an example of P-CT study (Figure 2) are given.

Considering that BV and PEI showed the most sustained significant modifications during treatment, sensibility, specificity, PPV and NPV and accuracy are calculated only for these two CT perfusion parameters and are reported in Table 3.

<b>Table 2 : Baseline and on treatment perfusion parameters</b>			
	<b>Responders</b>	<b>Non Responders</b>	<b>p</b>
<b>PF, ml/100 g of tissue/min</b>			
T0	148.1 (111.7)	82.8 (68.2)	0.098
T1	151.6 (110.9)	77.8 (87.7)	0.072
T2	169.2 (125.4)	98.9 (99.3)	0.127
Mean absolute (%) change T0-T2	+ 21.1 (+ 12.5%)	+ 16.1 (+ 16.3%)	
<b>TTP, seconds</b>			
T0	19.6 (14)	25.8 (18)	0.289
T1	17(12.3)	39.7 (27.7)	0.002
T2	21.7 (21.2)	39 (32.5)	0.078
Mean absolute (%) change T0-T2	+ 2.1 (+ 9.7%)	+ 13.2 (+ 33.8%)	
<b>PEI, HU</b>			
T0	72.8 (49.2)	39.4 (10.1)	0.043
T1	62.5 (37.1)	48.2 (22.6)	0.268
T2	58.7 (30.8)	45.2 (15.4)	0.202
Mean absolute (%) change T0-T2	- 14.1 (-24%)	+ 5.8 (+ 12.9%)	
<b>BV, ml/100 g of tissue</b>			
T0	51.7 (30.8)	70.6 (32.3)	0.121
T1	61.9 (28.1)	46.8 (24.4)	0.150
T2	124.1 (73.7)	39.9 (17.5)	0.001
Mean absolute (%) change T0-T2	+ 72.4 (+ 58.3%)	- 30.7 (- 76.9%)	
<p>Mean values (SD) are reported. Differences between responder and non-responder lesions were assessed by means of One Way Anova test: PEI was the only perfusional parameter that significantly differed between the two groups at baseline. Legend: PF: perfusion; TTP: time to peak; PEI: peak enhancement intensity; BV: blood volume.</p> <p>Differences between responder and non-responder lesions were assessed by means of One Way Anova test.</p> <p>T1: +2 months; T2: +4 months</p>			

**Figure 1: Baseline and on treatment differences in perfusion parameters between responder and non-responder lesions.** Blue boxes represent responder lesions while green boxes represent non-responder lesions. Three different time-points are considered: baseline (T0), after 2 months (T1) and after 4 months (T2) of everolimus treatment. Legend: PF: perfusion (expressed as ml/100 g of tissue/min); TTP: time to peak (expressed in seconds); PEI: peak enhancement intensity (expressed in HU); BV: blood volume (expressed as ml/100 g of tissue).



**Figure 2: Examples of perfusion CT study.** Responding liver lesions during everolimus treatment at baseline (Figure 1a), after 2 months (Figure 1b) and 4 months (Figure 1c). Non-responding liver lesions during everolimus treatment at baseline (Figure 1d), after 2 months (Figure 1e) and 4 months (Figure 1f).

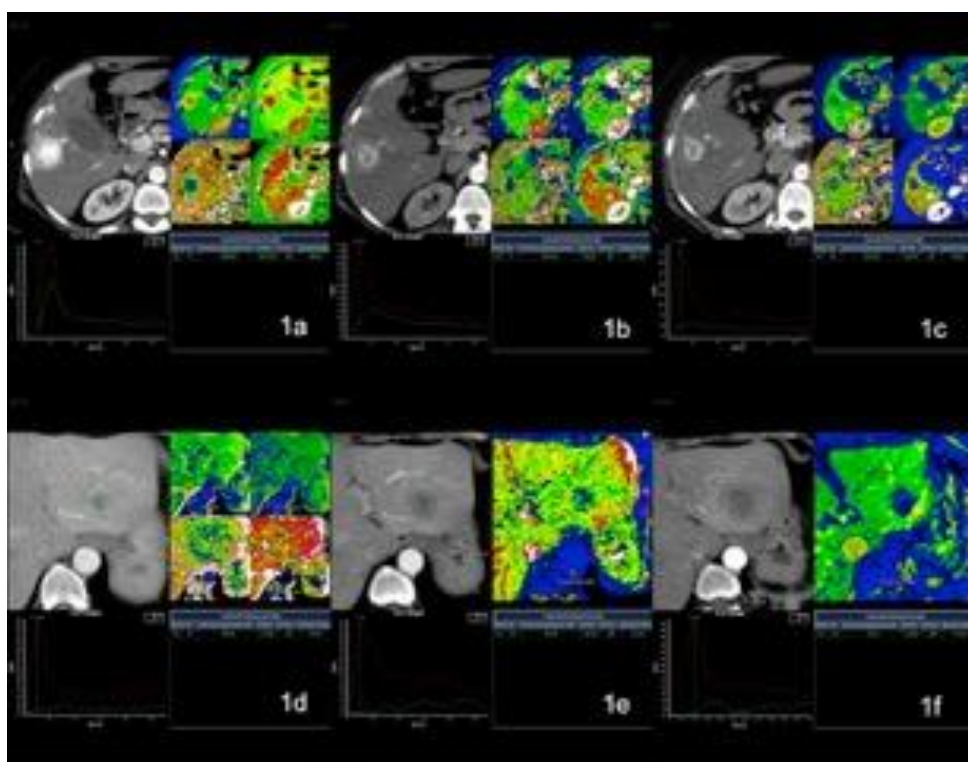




Table 3 : Statistical outcomes of relevant perfusional parameters.							
	sensitivity	specificity	PPV	NPV	accuracy	positive LR	negative LR
<b>BV ↑(T1)</b>	73.91%	80%	89.47%	57.14%	75.76%	3.7	0.33
<b>BV ↑(T2)</b>	86.96%	80%	90.91%	72.73%	84.85%	4.35	0.16
<b>PEI ↓ (T1)</b>	80%	69.23%	80%	69.23%	75.76%	2.6	0.29
<b>PEI ↓ (T2)</b>	65.22%	60%	78.95%	42.86%	63.64%	1.63	0.58
<b>BV ↑+ PEI ↓ (T1)</b>	56.52%	80%	86.67%	44.44%	63.63%	2.83	0.54
<b>BV ↑ + PEI ↓ (T2)</b>	65.22%	80%	88.24%	50%	69.70%	3.26	0.43
BV: blood volume; PEI: peak enhancement intensity; PPV positive predictive value; NPV: negative predictive value; T1: +2 months; T2: +4 months							

## Discussion

Perfusion CT (P-CT) is an imaging technique able to quantify tissue vascularization and perfusion. In oncologic imaging, P-CT finds application in tumor assessment, characterization and staging; its role in predicting and monitoring response to therapy is still under evaluation.

Blood flow assessed by P-CT had demonstrated a strong correlation with intratumoral MVD, microscopic vascular involvement, and tumour size and tumour grade in pancreatic neuroendocrine tumours, resulting significantly higher in G1-2 than in G3 tumors. Similarly, other perfusion parameters, as mean transit time, resulted significantly longer in patients with nodal involvement or liver metastases [24].

Two studies evaluated the role of P-CT as a functional biomarker of treatment response in well-differentiated neuroendocrine tumours of different sites of origin. Ng et al. [25] evaluated 24 patients treated with bevacizumab or interferon. Bevacizumab induced a significant reduction in mean blood flow and blood volume compared with baseline; these modifications onset 2 days after treatment start and remained unchanged at 18 weeks. Notably, bevacizumab decreased tumour blood flow by a fixed percentage relative to baseline measurements. No significant changes in P-CT parameters were found in patients treated with interferon; however, when bevacizumab was added to IFN, the same changes in blood flow and blood volume seen with bevacizumab monotherapy were found [25]. Yao et al. [26]

evaluated 39 patients treated with bevacizumab and everolimus, alone and in combination. In this study, the absolute decrease in tumour PF following bevacizumab and everolimus correlated with baseline PF and treatment led to a proportional decrease in such parameter. Specifically, single-agent bevacizumab was associated with a significant decrease in PF after 3 weeks of treatment; a further decrease was observed when everolimus was added at week 9, most probably caused by the addition of everolimus itself. However, single agent everolimus was associated with only a non-statistically significant decrease in PF; the subsequent addition bevacizumab led to a further, significant decrease of PF at week 9. Bevacizumab therapy was also associated with significant decrease in BV and permeability surface (PS), while mean transit time (MTT) was not affected; conversely, everolimus treatment determined a significant increase in MTT without affecting BV or PS. Although patients with higher baseline PS, lower post-treatment PF or higher post treatment MTT had greater percentage reduction in sum of the RECIST tumour measurements, no significant correlation between P-CT parameters and clinical outcome (progression free survival, PFS) was observed, maybe due to the small number of PFS events observed at the time of publication [27]. It should be noted that bevacizumab, a humanized monoclonal antibody that specifically blocks VEGF-A, is a direct antiangiogenic agent: through the inhibition of VEGF binding to its receptors Flt-1 (VEGFR-1) e KDR (VEGFR-2) on endothelial cells, bevacizumab induces regression and normalization of the tumour vascularisation, and inhibition of neo-vascularization, thus leading to an impaired tumour growth [28].

Everolimus, an m-TOR inhibitor, has instead indirect anti-angiogenic activity through the modification of gene expression and intracellular activity mediated by the inhibition of the PI3K/Akt/mTOR pathway, finally leading to *in vitro* inhibition of endothelial and stromal cells growth, reduction of VEGF release from tumor cells [29]. The different mechanism of action of these two drugs may at least partially explain the different timing and kind of perfusion modification.

Antiangiogenic agents are often associated with a low response rate according to RECIST criteria, though determining significant clinical benefit in terms of PFS and/or OS. In the phase III trial of everolimus in PanNETs [6], the observed benefit from everolimus with respect to PFS was primarily dependent on stabilization of disease or minor tumour shrinkage, and on the lower incidence of progressive disease: confirmed objective tumour responses (all partial response, PR) were observed in only 5% of patients receiving the study drug, while stable disease (SD) was evident in 73% of cases. For this reason, standard response criteria based on dimensional modifications of target lesions during treatment are generally considered sub-optimal to assess response to targeted agents, and there is an urgent need of other tools with a better predictive value for response.

In our study, conducted with the aim of evaluating perfusion CT parameters of PanNET liver metastases treated with everolimus, after describing morphological features of the target lesions, we recorded baseline perfusion values and treatment induced modifications, and analysed possible correlations with response.

The morphologic analysis led to the observation, as expected, of a prevalent hyper vascular pattern of liver metastases from PanNET; although lesions classified as hyper vascular at baseline seemed more likely to respond, there was no significant association between qualitative/visual analysis of vascularisation and response to treatment (hyper vascular versus iso/hypo vascular,  $p$  0.433). Responder lesions were significantly larger than non-responder lesions at baseline both in the completely cystic ( $p < 0.001$ ) and in the subset of hyper vascular lesions ( $p$  0.004).

The perfusion analysis demonstrated that, at baseline, only PEI was significantly correlated with response, resulting significantly higher in responder compared to non-responder lesions ( $p$  0.043). The few number of cases included does not allow to propose possible predictive cut-offs, but this observation deserves further studies.

Treatment with everolimus led to relevant modifications in three out of four P-CT parameters: TTP, PEI and BV.

Considering TTP, an early (T1) increase was observed in non-responder lesions, leading to higher mean TTP values in

nonresponder compared to responder lesions at T1 ( $p$  0.002); however, such between-groups difference was not maintained at T2 ( $p$  0.078), and a TTP increase at any time during the study period was not significantly associated with response.

On the contrary, a constant, borderline significant decrease in PEI was observed in responding but not in non-responding lesions, and a PEI decrease at any time of the study period was significantly associated with response ( $p$  0.014).

However, the most relevant and sustained post-treatment perfusion modification observed regarded BV. Although no differences were found in mean BV values between responder- and non-responder lesions at baseline ( $p$  0.121), an early and significant trend towards BV increase was observed both at T1 ( $p$  0.004) and T2 ( $p < 0.001$ ) in responding lesions. Higher absolute mean values, comparing responding versus non-responding lesions, were observed at T2 (124.11 +/- 73.75 and 39.9 +/- 17.52 ml/100 g of tissue, respectively;  $p < 0.001$ ).

Understanding intratumoral vascular changes during everolimus treatment needs to take into account pharmacodynamics in respect to other targeted agents. In fact while bevacizumab induces regression and normalization of the tumour vascularisation and inhibition of neo-vascularization with a reported BV decrease [25-27], everolimus, an m-TOR inhibitor, has indirect anti-angiogenic activity through the modification of gene expression and intracellular activity mediated by the inhibition of the PI3K/Akt/mTOR pathway, leading to inhibition of endothelial and stromal cells growth possibly with a disruption of the vascular integrity and a blood leakage in the extravascular space. Blood volume, as milliliters of contrast material on 100 grams of tissue, increases in relation to the increasing permeability. Intratumoral contrast medium accumulation, detected as volume during time along the examination study, seems therefore the most early and sustained modification detectable at P-CT associated with everolimus treatment benefit. Such modification has extremely high accuracy and positive predictive value for response even at an early evaluation, after 2 months of therapy (accuracy: 75.76%; PPV: 89.47%), performing even better after 4 months (84.85% and 90.91%, respectively); the integration of other perfusion parameter modifications, such as PEI decrease, does not improve the predictive strength of BV increase (Table 3). Interestingly, these perfusion modifications are detectable earlier than the size modifications required by standard response criteria, and this is particularly relevant when applied to a drug such as everolimus that typically has only minor impact on tumour size and to a disease with a generally indolent behaviour, such as well-differentiated neuroendocrine tumours.

This study has several limits. First, the number of patients evaluated with P-CT was relatively small; for this reason, our observations should be seen as hypothesis generating, to be confirmed by further prospective studies. However, it should be noticed that clinical outcomes in terms of response rate, disease control rate and mean progression free survival observed in our casistic were similar to those reported in the literature for PanNETs treated with everolimus, thus our sample could be considered as representative of the general population.

Another main limitation of this study relays in our arbitrary definition of 'responder' patient or lesion on the basis of a dimensional stability lasting at least 11 months, derived from the mPFS observed in the registrative trial of everolimus in PanNETs [6]; however, in the absence of standardized objective criteria for definition of everolimus benefit, this cut-off seemed the most reliable for the purpose of our study.

Another limit is related to the differences in the perfusional analysis performed and the different perfusional parameters analysed by different CT scanner vendors. This fact may limit the comparability of different perfusional studies performed in different centres.

In conclusion, this study shows that everolimus treatment leads to modification of P-CT parameters in liver metastases from PanNET; the most relevant and sustained modification seems to be an early and significant increase of BV, that may be associated with response to treatment. Further studies and longer follow up are required to confirm these preliminary observations and to validate BV as a predictive biomarker; however, the data reported suggest that perfusion CT may have a role in better (and possibly earlier) stratify patients with tumour response to treatment.

## References

1. Yao JC, Eisner MP, Leary C, Dagohoy C, Phan A, et al. (2007) Population-Based Study of Islet Cell Carcinoma. *Ann Surg Oncol* 4(12): 3492-3500.
2. Modlin IM, Oberg K, Chung DC, Jensen RT, de Herder WW, et al. (2008) Gastroenteropancreatic neuroendocrine tumours. *Lancet Oncol* 9(1): 61-72.
3. Yao JC, Hassan M, Phan A, Dagohoy C, Leary C, et al. (2008) One hundred years after "carcinoid": epidemiology of and prognostic factors for neuroendocrine tumors in 35,825 cases in the United States. *J Clin Oncol* 26(18): 3063-7
4. Zhang J, Jia Z, Li Q, Wang L, Rashid A, et al. (2007) Elevated expression of vascular endothelial growth factor correlates with increased angiogenesis and decreased progression-free survival among patients with low-grade neuroendocrine tumors. *Cancer* 109(8): 1478-1486.
5. Raymond E, Dahan L, Raoul JL, Bang YJ, Borbath I, et al. (2011) Sunitinib Malate for the Treatment of Pancreatic Neuroendocrine Tumors *N Engl J Med.* 364(11): 501-13.
6. Yao JC, Shah MH, Ito T, Bohas CL, Wolin EM, et al. (2011) Everolimus for Advanced Pancreatic Neuroendocrine Tumors. *N Engl J Med.* 364(6): 514-23.
7. Eisenhauer EA, Therasse P, Bogaerts J, Schwartz LH, Sargent D, et al. (2009) New response evaluation criteria in solid tumours: Revised RECIST guideline (version 1.1). *Eur J Cancer* 45(2): 228-247.
8. Nishino M, Jagannathan JP, Krajewski KM, O'Regan K, Hatabu H, et al. (2012) Personalized Tumor Response Assessment in the Era of Molecular Medicine: Cancer-Specific and Therapy-Specific Response Criteria to Complement Pitfalls of RECIST. *AJR Am J Roentgenol* 198(4): 737-745.
9. Choi H, Charnsangavej C, Faria SC, Macapinlac HA, Burgess MA, et al. (2007) Correlation of computed tomography and positron emission tomography in patients with metastatic gastrointestinal stromal tumor treated at a single institution with imatinib mesylate: proposal of new computed tomography response criteria. *J Clin Oncol* 25: 1753-1759.
10. Bruix J, Sherman M, Llovet JM, Beaugrand M, Lencioni R, et al. (2001) Clinical management of hepatocellular carcinoma. Conclusions of the Barcelona- 2000 EASL conference. European Association for the Study of the Liver. *J Hepatol* 35: 421-430.
11. Lencioni R, Llovet JM (2010) Modified RECIST (mRECIST) assessment for hepatocellular carcinoma. *Semin Liver Dis.* 30: 52-60.
12. Llovet JM, Di Bisceglie AM, Bruix J, Kramer BS, Lencioni R, et al. (2008) Design and endpoints of clinical trials in hepatocellular carcinoma. *J Natl Cancer Inst* 100: 698-711.
13. Ronot M, Bouattour M, Wassermann J, Bruno O, Dreyer C, et al. (2014) Alternative Response Criteria (Choi, European association for the study of the liver, and modified Response Evaluation Criteria in Solid Tumors [RECIST]) Versus RECIST 1.1 in patients with advanced hepatocellular carcinoma treated with sorafenib. *Oncologist* 19(4): 394-402.
14. Sahani DV, Kalva SP, Hamberg LM, Hahn PF, Willett CG, et al. (2005) Assessing Tumor Perfusion and Treatment Response in Rectal Cancer with Multisection CT: Initial Observations. *Radiology* 234: 785-792.
15. Roberts HC, Roberts TP, Lee TY, Dillon WP (2002) Dynamic, contrast-enhanced CT in human brain tumors: quantitative assessment of blood volume, blood flow, and microvascular permeability. *Am J Neuroradiol* 23: 828-832.

16. Groell R, Kugler C, Aschauer M, Rienmueller R, Stauber R, et al. (1995) Quantitative perfusion parameters of focal nodular hyperplasia and normal liver parenchyma as determined by electron beam tomography. *Br J Radiol* 68: 1185–1193.
17. Zhang M, Kono M (1997) Solitary pulmonary nodules: evaluation of blood flow patterns with dynamic CT. *Radiology* 205: 471–478.
18. Ng QS, Goh V, Fichte H, Klotz E, Fernie P, et al. (2006) Lung Cancer Perfusion at Multi-Detector Row CT: Reproducibility of Whole Tumor Quantitative Measurements. *Radiology* 239: 547–553.
19. Ohno Y, Koyama H, Matsumoto K, Onishi Y, Takenaka D, et al. (2011) Differentiation of Malignant and Benign Pulmonary Nodules with Quantitative First-Pass 320-Detector Row Perfusion CT versus FDG PET/CT. *Radiology* 258: 599–609.
20. Blomley MJ, Coulden R, Bufkin C, Lipton MC, Dawson P (1993) Contrast bolus dynamic computed tomography for the measurement of solid organ perfusion. *Invest Radiol* 28(S5): S72–S77.
21. Park MS, Klotz E, Kim MJ, Song SY, Park SW, et al. (2009) Perfusion CT: Non-invasive Surrogate Marker for Stratification of Pancreatic Cancer Response to Concurrent Chemo - and Radiation Therapy. *Radiology* 250: 110-117.
22. Hermans R, Lambin P, Van der Goten A, Van den Bogaert W, Verbist B, et al. (1999) Tumoral perfusion as measured by dynamic computed tomography in head and neck carcinoma. *Radiother Oncol* 53: 105–111.
23. Faggioni L, Neri E, Bartolozzi C (2010) CT Perfusion of Head and Neck Tumors: How We Do It. *Am J Roentgenol* 194: 62–69.
24. d'Assignies G, Couvelard A, Bahrami S, Vullierme MP, Hammel P, et al. (2009) Pancreatic Endocrine Tumors: Tumor Blood Flow Assessed with Perfusion CT Reflects Angiogenesis and Correlates with Prognostic Factors. *Radiology* 250: 407–416.
25. Ng CS, Charnsangavej C, Wei W, Yao JC (2011) Perfusion CT Findings in Patients with Metastatic Carcinoid Tumors Undergoing Bevacizumab and Interferon Therapy. *Am J Roentgenol* 196: 569–576.
26. Yao JC, Phan A, Hoff PM, Chen HX, Charnsangavej C, et al. (2008) Targeting Vascular Endothelial Growth Factor in Advanced Carcinoid Tumor: A Random Assignment Phase II Study of Depot Octreotide with Bevacizumab and Pegylated Interferon Alfa-2b. *J Clin Oncol* 26: 1316-1323.
27. Yao JC, Phan A, Hess K, Fogelman D, Jacobs C, et al. (2015) Perfusion Computed Tomography as Functional Biomarker in Randomized Run-In Study of Bevacizumab and Everolimus in Well-Differentiated Neuroendocrine Tumors. *Pancreas* 44: 190–197.
28. Ranieri G, Patruno R, Ruggieri E, Montemurro S, Valerio P, et al. (2006) Vascular endothelial growth factor (VEGF) as a target of bevacizumab in cancer: from the biology to the clinic. *Curr Med Chem* 13(16): 1845-57.
29. Honer M, Ebenhan T, Allegrini PR, Ametamey SM, Becquet M, et al. (2010) Anti-Angiogenic/Vascular Effects of the mTOR Inhibitor Everolimus Are Not Detectable by FDG/FLT-PET. *Translat Oncol* 3: 264–275.

Please Submit your Manuscript to Cresco Online Publishing

<http://crescopublications.org/submitmanuscript.php>